

**DAVID H. NEUSTADT, MD***Clinical Professor of Medicine, University of
Louisville School of Medicine, Louisville, KY

Intra-articular injections for osteoarthritis of the knee

■ ABSTRACT

If usual medical measures fail to control the pain of knee osteoarthritis and allow the patient to cope with its symptoms, intra-articular injections of a corticosteroid, a hyaluronan, or both can be tried.

■ KEY POINTS

Osteoarthritis is now known to involve more than mechanical wear and tear, as believed in the past; inflammatory mechanisms are also at work.

Patient education should emphasize losing weight (in overweight patients) and modifying activities to reduce stress on the knees, as well as what to expect from intra-articular therapy.

A large, tense, or painful effusion is the strongest indication for prompt arthrocentesis and, if the synovial fluid is not infected, subsequent corticosteroid injection.

After a corticosteroid injection in the knee, the patient should remain in bed or at rest and avoid walking as much as possible for 3 days, and then use crutches or a cane for the next 2 to 3 weeks.

The major factors that influence the therapeutic response to intra-articular injections of hyaluronan are the severity of the disease and the extent of cartilage loss in the involved knee.

*The author has indicated that he has served as a consultant for the Ortho Biotech Products corporation.

INJECTION OF CORTICOSTEROIDS into painful joints—long a mainstay of therapy for rheumatoid arthritis—is now popular for osteoarthritis of the knee as well.

Logically, this use may seem surprising, since we used to be taught that osteoarthritis is due to “wear and tear,” not inflammation, and corticosteroids are powerful anti-inflammatory drugs. However, now we know that inflammation is present in most patients with symptomatic osteoarthritis. Moreover, this treatment often provides striking and lasting relief of pain, especially in patients with synovitis associated with chronic knee osteoarthritis.

A local (as opposed to a systemic) treatment for a painful joint has obvious appeal. Nevertheless, intra-articular corticosteroid therapy is essentially palliative and must be considered as adjunctive to other basic therapies.¹

Newer agents called hyaluronans are also given by intra-articular injection. In the synovial fluid they supplement endogenous hyaluronan, which serves as a lubricant and shock absorber.

This article reviews the rationale for and the practical aspects of intra-articular therapy with corticosteroids and hyaluronan preparations in osteoarthritis.

■ OSTEOARTHRITIS IS COMMON

Osteoarthritis (also called degenerative joint disease and osteoarthrosis) is by far the most common form of arthritis and the major cause of disability and reduced activity in people older than 50 years.²

The joint most often affected is the knee. According to some population surveys, 30% of people older than 50 years have radiographic

evidence of osteoarthritis of the knee, increasing to up to 80% after age 65. In the United States, approximately 100,000 people are unable to walk independently from bed to bathroom owing to pain and disability caused by osteoarthritis of the knees. About 300,000 knee joints were surgically replaced in 2005.³

Men have more knee osteoarthritis before age 50, but its incidence in women rises after menopause, and by age 65 the prevalence is twice as high in women as in men.⁴

■ NOT JUST WEAR AND TEAR

Osteoarthritis is characterized by cartilage involvement, varying from microfissures and fibrillations in early disease to virtual destruction with bone-on-bone contact in advanced disease. Osteophytes (spurs) develop at the margins of joints, and new cartilage proliferates over these bony spurs.

During the past decade much has been learned about cartilage, including metabolic changes, genetic mutations, metalloproteinases, and inflammatory mediators, fostering considerable excitement and interest in new approaches for preventing and treating osteoarthritis.

Although the specific cause of osteoarthritis remains unknown, contributing and risk factors include:

- Aging
- Genetic factors
- Overweight and obesity
- Overuse of the joints (as in occupational and sports activities)
- Trauma
- Malalignment of the knee
- Muscle weakness.

Osteoarthritis may be considered a “final common pathway” resulting from a host of these different problems, or it may be considered as primary or idiopathic when none of these risk factors can be identified.

■ MANAGEMENT IS INDIVIDUALIZED

No specific therapy has yet been clearly shown to prevent the progression of osteoarthritis. The goal is to suppress pain and improve function, with special attention to the patient's ability to rise from a low seat and walk with

relative comfort. Therapy is individualized on the basis of the symptoms and severity of the disease; options range from simple advice about modifying activity to joint replacement.

Nonpharmacologic measures are important

Some of the most important nonpharmacologic measures aim at “deloading” the knee. Patients should try to lose weight if needed and protect the knees by avoiding up-and-down impact on them, using walking aids such as canes and crutches. They should also avoid climbing stairs and should regularly do isometric exercise to strengthen the quadriceps muscles.

Some patients with osteoarthritis of the medial compartment of the knee get some relief by placing wedges in their shoes in the lateral heel and insole.⁵ In a study of 85 patients (with 121 osteoarthritic knees) treated for approximately 1 year, 61% reported a favorable response to this simple measure.^{5,6}

Of paramount importance is patient education. It should emphasize what to expect and the importance of losing weight, especially in vastly overweight patients, and of modifying their activities.

Simple analgesics, NSAIDs for minimal pain

If pain is minimal, it may be controlled with simple analgesics such as acetaminophen (Tylenol), propoxyphene (Darvon), or tramadol (Ultram). Undesirable effects of these medications are usually minor, but patients with preexisting renal or liver conditions must exercise special caution.

If simple analgesics do not adequately control the pain, one can add a nonsteroidal anti-inflammatory drug (NSAID). The many traditional (nonselective) NSAIDs all have similar efficacy, but they differ in gastrointestinal toxicity and in the number of tablets or capsules that need to be taken to reach the appropriate dose. The newer cyclooxygenase-2-specific NSAIDs are as effective as the older, nonselective NSAIDs and have fewer gastrointestinal side effects, but they are much more costly and some appear to increase the risk of cardiovascular events.

Intra-articular injections

Concerned about possible side effects of selective and nonselective NSAIDs, physicians are

Options range from simple advice to joint replacement

increasingly considering intra-articular treatment when simple measures are inadequate.

Some intra-articular treatments have not been beneficial. In a randomized study in 180 patients with osteoarthritis of the knee, joint lavage with saline was no more beneficial than a sham procedure.⁷ Arthroscopy with or without debridement is also ineffective in osteoarthritis of the knee unless secondary damage such as troublesome loose bodies or a torn meniscus is present, requiring surgical repair.⁸

On the other hand, intra-articular corticosteroid therapy is often successful in knee osteoarthritis associated with synovitis and effusion. Steroid injections may be given up to three or four times per year. Injections of hyaluronans also seem to work. These therapies are the focus of the rest of this article.

Knee replacement when medical therapy fails

Knee replacement is reserved for patients for whom medical management (including injection therapy) fails, and for those who have intractable pain and disability.

■ INTRA-ARTICULAR CORTICOSTEROIDS

Hydrocortisone was introduced for intra-articular injection in 1951. Since then, vast experience has confirmed the value of this agent and of other corticosteroid suspensions for combating pain and inflammation when injected into the joint in patients with rheumatoid arthritis and other inflammatory arthropathies.⁹

Their use in osteoarthritis has been controversial, however. Early studies in mice, rats, and rabbits suggested that multiple corticosteroid injections might alter cartilage protein synthesis and consequently damage the cartilage.¹⁰⁻¹⁴ These deleterious effects curbed early enthusiasm for intra-articular corticosteroid therapy in osteoarthritis.

However, the knee joints of patients who received multiple intra-articular injections of steroids showed no significant evidence of destruction or accelerated deterioration.^{15,16} A detailed study of intra-articular steroid injections in monkeys also disclosed no appreciable joint damage, suggesting that primates' joints respond differently than those of rodents.¹⁷

Most authorities now consider intra-articular corticosteroid therapy for osteoarthritis of considerable value when used appropriately and judiciously.¹⁸

Metabolism of corticosteroid suspensions: Systemic absorption may occur

The metabolic pathway and ultimate fate of corticosteroids within the joint have not been completely elucidated.¹⁰ Injected steroids can be detected in synovial fluid cells for 48 hours after injection.¹⁹ The rate of absorption and the duration of action are related to the solubility of the compound injected. Triamcinolone hexacetonide (Aristospan) is the most insoluble preparation currently available.²⁰

Systemic absorption may occur, varying with the dose and the solubility of the preparation. One study showed that 40 mg of intra-articular methylprednisolone acetate (Depo-Medrol) was sufficient to transiently suppress adrenal function, as reflected in depressed cortisol levels for up to 7 days.¹⁹ We ask patients to limit their activity after injections, as it may delay escape of the steroid and minimize systemic effects (see below).

Therapeutic rationale for corticosteroids

Corticosteroids inhibit prostaglandin synthesis and decrease the activity of collagenase and other enzymes. Their major mechanism of benefit in osteoarthritis, however, remains unclear. Saxne et al²¹ measured the release of proteoglycans into synovial fluid to monitor the effects of therapy on cartilage metabolism. Their data strongly suggest that intra-articular corticosteroid injections reduce the production of interleukin-1, tumor necrosis factor alpha, and proteases that may degrade the cartilage.

Indications for intra-articular steroids

Intra-articular therapy must be considered an adjunct to basic measures.

For assessment. By examining the gross appearance and viscosity of the synovial fluid obtained by aspiration, an experienced observer can usually distinguish whether a rheumatoid, traumatic, or osteoarthritic process is present. Only a few drops of fluid may suffice to establish the diagnosis of gout or pseudogout.

For therapy. When conventional therapy fails to control symptoms or prevent disability,

Important first steps: Lose weight, reduce impact on the knees

local steroid therapy deserves consideration. A large, tense, or painful effusion is the strongest indication for prompt arthrocentesis and, if the fluid is relatively clear and does not appear to be infected or purulent, subsequent corticosteroid injection.

Joint injections often help prevent adhesions and correct flexion deformities of the knee. If the joint is large, tense, or boggy due to an effusion, the capsule and ligaments may become stretched; this condition can be combated effectively with intra-articular therapy.

Finally, if an effusion of the knee is long-standing or recurs, a “medical synovectomy” can be performed by instilling a relatively large dose (30–50 mg) of an insoluble preparation such as triamcinolone hexacetonide, followed by a strict regimen of rest.

Steroids are clinically effective

Favorable reports on the use of intra-articular steroids in osteoarthritis are numerous.^{15,18,22–26}

Hollander²⁰ reported on 30 years of experience with a large number of injections. In a 10-year follow-up of the first 100 patients who had been given repeated intra-articular steroid injections in osteoarthritic knees, 59 patients no longer needed injections, 24 continued to require occasional injections, and only 11 did not obtain a worthwhile response.²⁶ My own experience is similar: most patients experience striking relief of pain, frequently coupled with improved motion, in the treated joints.

Although some controlled trials found steroid injections ineffective, they did not take into consideration such important factors as adequate dosage, the presence or absence of fluid, removal of excess fluid (so that the drug is not diluted), and the injection technique.^{27,28} Most importantly, there was no attempt to regulate the postinjection physical activity of the patient.

Dieppe et al²⁹ gave injections of either triamcinolone hexacetonide 20 mg or placebo in 48 osteoarthritic knees; reduction of pain and tenderness was significantly greater with the active drug.

Valtonen³⁰ gave injections of either triamcinolone hexacetonide or betamethasone acetate-betamethasone disodium to 42 patients with osteoarthritis; both of these steroids were highly effective.

Other studies also showed favorable results.³¹ The duration of effect varied with the preparation and the dosage.

Contraindications to intra-articular corticosteroids are relative

Contraindications to intra-articular corticosteroid injections are relative.

- **Infection.** Local infection, recent serious injury over the structure to receive the injection, and generalized infection with possible bacteremia are obvious contraindications to the instillation of a corticosteroid. In patients with systemic infections, intra-articular therapy might be given under the cover of appropriate antibiotic therapy, if it is urgently needed.

- **Anticoagulant therapy.** The risk of provoking serious bleeding in patients receiving anticoagulants must be assessed after reviewing the patient's general status, including the prothrombin time.³²

- **Uncontrolled diabetes mellitus.**

- **Severe joint destruction or deformity,** such as an unstable knee, should preclude corticosteroid injections unless a relatively large inflammatory effusion is present and the patient agrees to avoid weight-bearing activity for several weeks after the procedure.

- **Obesity** that is severe enough to make penetration of the joint difficult and to greatly increase the load (impact) on the knee during weight-bearing and walking.

Complications are rare

The role of intra-articular corticosteroids in osteoarthritis remains somewhat controversial because of some reports of steroid-induced (Charcot-like) arthropathy developing after multiple injections.^{10,11} However, complications of intra-articular therapy are rare.

Systemic effects. Despite some systemic spillover, hypercortisonism and other undesirable steroid effects are rare. If the patient develops the “moon face” of Cushing syndrome, injections have probably been given too frequently.³³ Intra-articular steroids may induce mild to moderate transient hyperglycemia, which rarely causes a significant clinical problem except in patients with very brittle or uncontrolled diabetes mellitus.

Infection, the most serious complication, is also extremely rare.^{10,20,34}

Charcot-like arthropathy has developed after multiple injections, but this is rare



TABLE 1

Some corticosteroid suspensions for intra-articular injection

PREPARATIONS	CONCENTRATION (MG/ML)	USUAL DOSE (MG)*
Hydrocortisone tebutate (Hydrocortone-TBA)	50	25–100
Betamethasone acetate and betamethasone sodium phosphate (Celestone Soluspan)	6 [†]	1.5–6
Methylprednisolone acetate (Depo-Medrol [‡])	20	4–40
Triamcinolone acetonide (Kenalog-40)	40	5–40
Triamcinolone diacetate (Aristocort Forte)	40	5–40
Triamcinolone hexacetonide (Aristospan)	20	5–40

*Amount injected varies depending on the size of the joint

[†]Available as 3 mg acetate and 3 mg phosphate

[‡]Available in 20 mg/mL, 40 mg/mL, and 80 mg/mL preparations

Postinjection flare. Local adverse reactions are minor and reversible. The so-called postinjection flare is a rare complication that begins shortly after the injection and usually subsides within a few hours, rarely continuing for 48 to 72 hours. Some investigators consider these reactions to be a true crystal-induced synovitis caused by corticosteroid ester microcrystals.^{10,35} Ice at the site of injection and oral analgesics usually control after-pain until the reaction abates. In a few instances, postinjection synovitis has been severe enough to require aspirating the joint again to relieve the pain.

Localized subcutaneous or cutaneous atrophy is also infrequent.^{9,10} This cosmetic change appears as a thin or depressed area at the injection site, sometimes associated with depigmentation. As a rule, the skin returns to normal when the crystals of the corticosteroid have been completely absorbed.

Capsular (periarticular) calcifications at the site of the injection have been noted in rare cases in radiographs taken after treatment. They usually disappear spontaneously and have no clinical significance.³⁶

Careful technique, avoiding leakage of the steroid suspension from the needle track

to the skin surface, will prevent or minimize these problems. A small amount of 1% lidocaine (or its equivalent) or normal saline solution can be used to flush the needle before it is removed.

Other complications. Occasionally, a patient may complain of increased warmth and flushing of the skin. Central nervous system and cardiovascular reactions to local anesthetics may also occur if they are combined with the steroid for injection.

Overuse. Some suggest that steroids, by abolishing pain, permit the patient to overwork the involved joint, further damaging the cartilage and bone and giving rise to a Charcot-like or neuropathic arthropathy.³⁷

As stated earlier, studies in nonhuman primates suggest that the steroid effect on human joints is probably transient.¹⁹ Indeed, evidence of a protective effect of corticosteroids against cartilage damage and osteophyte formation has been shown with triamcinolone hexacetonide in guinea pigs.³⁸

Available corticosteroids and choice of drug

Available repository preparations commonly used for intra-articular injection are listed in

TABLE 1.

Triamcinolone hexacetonide is the least soluble of the injectable corticosteroids

How to give an intra-articular injection

To give an intra-articular injection you will need:

- 10-mL and 3-mL Luer-Lok syringes
- 25-gauge 7/8-inch needles
- 20-gauge 1 1/2-inch needles
- 22-gauge 1-inch or 1 1/2-inch needles
- Paper towels or drapes, disposable gloves
- Forceps, alcohol sponges, 4 × 4-inch gauze sponges
- Povidone-iodine solution (or equivalent) or other antimicrobial solution
- Lidocaine 1% (without epinephrine) or ethyl chloride skin refrigerant spray
- Tubes for culture and synovial fluid analysis (EDTA or heparin)
- Plastic adhesive bandages.

PREPARE THE INJECTION SITE

Injection of a steroid or any other agent into a joint requires meticulous aseptic technique. The point of entry is cleansed with an antibacterial cleanser (antimicrobial soap or an equivalent) or povidone-iodine solution. Then alcohol is sponged on the area. Sterile drapes and gloves are not ordinarily considered necessary.

INJECTION TECHNIQUES: GENERAL CONSIDERATIONS

Arthrocentesis is easy and relatively painless in a joint that is distended with fluid or when boggy synovial proliferation is present.

For most joints, the usual point of entry is on the extensor surface, avoiding the large nerves and major vessels that are usually present on the flexor surface. Optimal joint positioning should be accomplished to stretch the capsule and separate the joint ends to produce maximal enlargement and distraction of the joint or synovial cavity to be penetrated.

A local anesthetic may be desirable, especially if the joint is relatively dry or if only a small amount of fluid is present. A small skin wheal made by infiltration with lidocaine or an equivalent, or spraying (frosting) the skin with a vapocoolant such as chloroethane (ethyl chloride), usually provides adequate anesthesia.

Aspiration of as much synovial fluid as possible prior to instillation of the corticosteroid suspension reduces possible dilution.

After the drug is injected, it may be advisable to instill a small amount of air just before removing the needle to ensure adequate mixing and dispersion. Gentle manipulation, carrying the joint through its

full range of motion, also facilitates dispersion of the medication.

Tips on injection technique:

- Use a skin pencil to outline anatomical landmarks and site of needle entry.
- Stretch skin at site of needle insertion.
- Aspirate completely to remove any fluid and detect blood or septic fluid.
- Apply a 4 × 4-inch gauze sponge or cotton swab at site of needle withdrawal to minimize any bleeding.
- Reassure the patient and observe him or her for at least 10 or 15 minutes after the injection to avoid anxiety reaction.

TECHNIQUE FOR KNEE INJECTION

The knee joint contains the largest synovial space in the body and is the one most often treated. Visible or palpable effusions often develop, making it the easiest joint to enter and inject medication into. When a large amount of fluid is present, entry is as simple as puncturing a balloon.

Aspiration of the knee is usually performed with the patient supine with the knee supported and extended as much as possible. The usual site of entry is medial at about the midpoint of the patella or just below the point where a horizontal line tangential to the superior pole of the patella crosses a line parallel to the medial border. A 20-gauge needle 1.5 to 2 inches long is directed downward or upward, sliding into the joint space beneath the undersurface of the patella (**FIGURE 1**).

Aspiration of the knee can be facilitated by applying firm pressure with the palm cephalad to the patella over the site of the suprapatellar bursa (**FIGURE 1**). If cartilage is touched, the needle is withdrawn slightly and the fluid is aspirated.

A similar approach can be used on the lateral side, especially if the maximal fluid bulge is lateral. The lateral approach is especially convenient if there is a large effusion in the suprapatellar bursa. The point of penetration is lateral and superior to the patella.

The infrapatellar route, though used less often, is useful when the knee cannot be fully extended and only minimal fluid is present. With the knee flexed, the needle is directed either medially or laterally to the inferior patellar tendon and cephalad to the infrapatellar fat pad. It is difficult to obtain fluid with this approach.

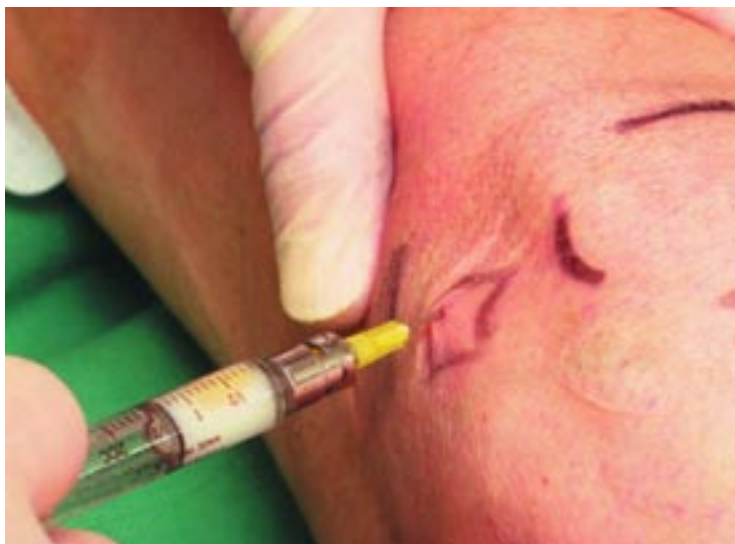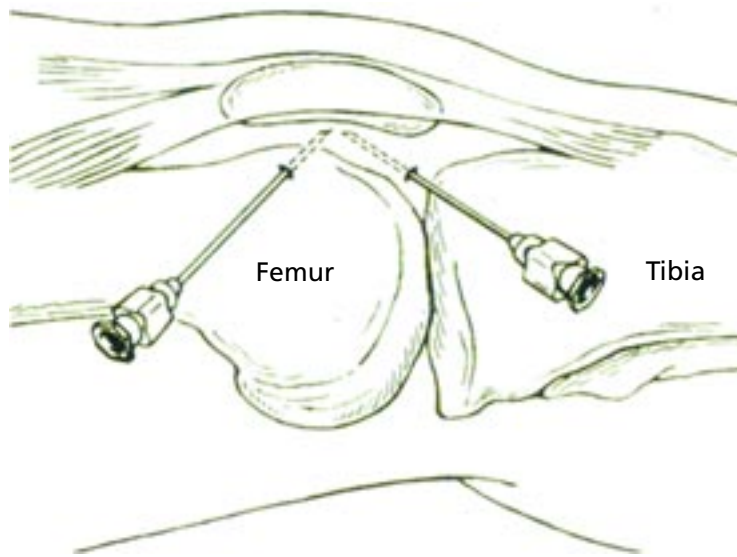


FIGURE 1. Top, arthrocentesis of the knee joint via the usual medial entry. Bottom, actual injection of corticosteroid suspension into knee via medial approach.

All injectable corticosteroids except cortisone and prednisone can promptly and significantly reduce inflammation in an inflamed joint. The more soluble the corticosteroid, the more rapidly it is absorbed and the shorter the duration of effect. Tertiary butyl acetate (TBA, tebutate) is an ester form that prolongs the duration of action of the compound as a result of decreased solubility, which probably causes its dissociation by enzymes to proceed more slowly.

Although a few patients may obtain greater benefit from one steroid than from

another, no single agent is convincingly superior except for triamcinolone hexacetonide.^{9,26,39} This is the least water-soluble preparation currently available (being 2.5 times less soluble in water than the others) and thus provides the longest duration of effect. Systemic spillover is minimal with this agent.

Dosing of corticosteroids

The dose of any microcrystalline suspension injected into a joint must be arbitrarily selected. Factors that influence the dose given and the anticipated results are the size of the joint, the volume of synovial fluid, the corticosteroid preparation chosen, the severity of synovitis, and whether the patient rests or is active after the injection. For estimating the dose, a useful guide is as follows:

- For small joints of the hand and foot, 2.5 to 10 mg of prednisolone tebutate suspension or an equivalent preparation
- For the knee, ankle, and shoulder, 20 to 40 mg
- For the hip, 25 to 40 mg
- For intrabursal therapy, such as for the trochanteric (hip) or the anserine (knee) bursa, 15 to 40 mg.

Larger doses are occasionally necessary to obtain optimal results.

I recommend waiting at least 4 weeks between intra-articular injections, and at least 8 to 12 weeks for weight-bearing joints. Injections should not be repeated on a regular routine basis, and rarely should more than two to three injections into a single weight-bearing joint be given per year.

Patients should rest after injections

After a corticosteroid injection in the knee, the patient should remain in bed or at rest and should walk as little as possible for 3 days, preferably only to the bathroom and to meals. After that, the patient should use crutches in a three-point gait to protect the injected knee during distance walking for the next 2 to 4 weeks. A cane can be used if crutches are inappropriate or uncomfortable.

This regimen prevents the patient from overworking the joint after the injection. An added benefit is that the inactivity reduces any systemic effect by delaying absorption of the steroid. This program is optimal for

achieving maximal therapeutic benefit.

During exercise, the intra-articular (hydrostatic) pressure increases considerably in inflamed human knees, causing intra-articular hypoxia.⁴⁰ After exercise, there is oxidative damage to lipids and immunoglobulin in the joint. The lipid peroxidation products in synovial fluid are not found in resting knees. The synovial membrane is reperfused when exercise is stopped.

■ PARA-ARTICULAR CAUSES OF KNEE PAIN

Knee pain and associated disabling symptoms sometimes result from para-articular causes, even if there is radiographic evidence of osteoarthritic changes in the knee. Some of these painful conditions may respond to local injection therapy.

These disorders include bursitides of the knee with involvement of the prepatellar, suprapatellar, and anserine bursae. Other disorders adjacent to the knee that may respond to injection therapy include semimembranosus tenosynovitis and painful points around the edge of the patella associated with patellofemoral osteoarthritis.

The differential diagnosis between osteoarthritis of the knee and these disorders is based on a thorough history and physical findings.

Prepatellar bursitis

Prepatellar bursitis (housemaid's, nun's, or carpet cutter's knee), characterized by swelling and effusion of the superficial bursa overlying the patella, is easily recognized. The chronic bursal reaction commonly arises from repetitive activity or pressure, such as kneeling on a firm surface. Pain is relatively minimal except on direct pressure, and motion is usually preserved.

Aspiration is performed, which may yield a small amount of clear, serous fluid, and then 1 to 2 mL of lidocaine and 10 to 20 mg of a corticosteroid suspension is instilled. Whenever possible, the activity provoking the bursitis should be eliminated.

Suprapatellar bursitis

Suprapatellar bursitis is usually associated with synovitis of the knee cavity. Occasionally the suprapatellar bursa is largely separated devel-

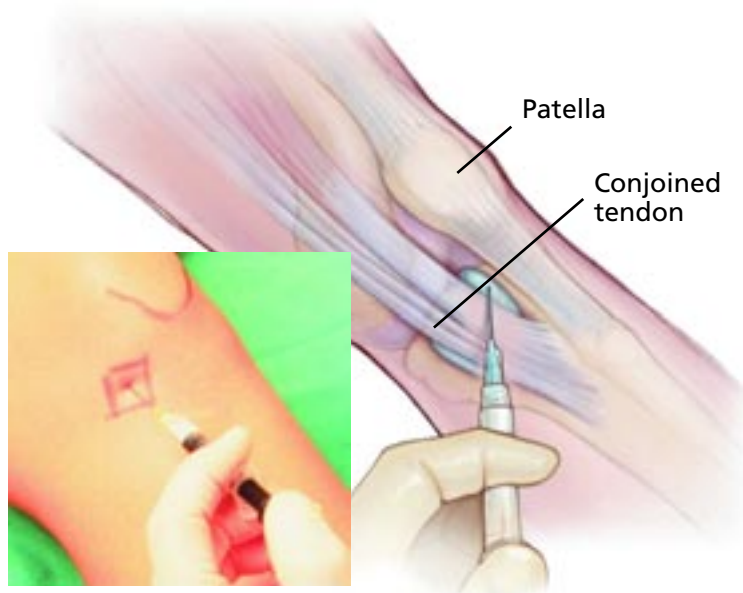


FIGURE 2. Injection into the anserine bursa. The needle is inserted medial to the tibial tuberosity (crest).

opmentally from the synovial cavity. In these cases, effusion is especially prominent in the suprapatellar region.

Anserine bursitis

Anserine bursitis (“cavalryman’s disease”) now mainly occurs in association with osteoarthritis of the knee in obese women with disproportionately heavy thighs. The bursa is located at the anteriomedial surface of the tibia just below the joint line of the knee, at the site of the insertion of the conjoined tendon of the sartorius, semitendinosus, and gracilis muscles, and superficial to the medial collateral ligament.

Anserine bursitis can mimic or coexist with osteoarthritis of the knee. A relatively abrupt increase in knee pain, localized tenderness with a sensation of fullness in the vicinity of the site of the bursa, or the development of an angular knee deformity strongly suggest this often-overlooked disorder.

Injection of 1 to 2 mL of lidocaine and approximately 1 to 1.5 mL of a corticosteroid suspension from an anteriomedial approach with a 1.5-inch, 20-gauge or 22-gauge needle frequently produces prompt symptomatic relief (**FIGURE 2**). The duration of effect is variable and may correlate with the patient’s weight-bearing activities.

Wait at least 8 to 12 weeks between corticosteroid injections in weight-bearing joints

TABLE 2

Approved hyaluronan preparations

	SODIUM HYALURONATE (HYALGAN)	SODIUM HYALURONATE (SUPARTZ)	HIGH-MOLECULAR- WEIGHT HYALURONAN (ORTHOVISC)	HYLAN G-F 20 (SYNVISC)
Type of product	Natural	Natural	Natural	Chemically cross-linked
Molecular weight (X 10 ⁶ daltons)	0.5–0.73	0.6–1.2	1.0–2.9	6.0
Concentration (mg/mL)	10	10	15	8
Dose volume (mL)	2	2.5	2	2
Dose interval	1 week	1 week	1 week	1 week
Number of doses	3 to 5	5	3 or 4	3

■ CRYSTAL SYNOVITIS AND OSTEOARTHRITIS (CHONDROCALCINOSIS)

Calcium pyrophosphate dihydrate deposition

The link between osteoarthritis and calcium pyrophosphate dihydrate deposition is extremely strong. About 70% of cases of deposition are associated with a chronic arthritis identical to osteoarthritis, usually involving the hips and the knees.⁴¹ In patients who develop an acute or subacute attack (“pseudogout”), arthrocentesis permits diagnostic confirmation and thorough aspiration of synovial fluid. From 1 to 2 mL of a corticosteroid suspension generally suppresses the inflammatory process in the knee.

Hydroxyapatite crystals and osteoarthritis

The possible relationship between hydroxyapatite crystal deposition and osteoarthritis was first reported by Dieppe et al⁴² in 1976. The notion that inflammation might be caused by apatite crystals was based on the finding of the crystals in synovial fluid from osteoarthritic patients.

Although apatite crystals are difficult to recognize clinically, when acute or subacute arthritis with an effusion develops, especially in patients on dialysis, it is reasonable to aspirate the contents of the synovial cavity and instill a corticosteroid suspension. Specific diagnosis is made by electron microscopy or x-ray diffraction of the crystals.

■ HYALURONAN PRODUCTS

Hyaluronan is a glycosaminoglycan polysaccharide composed of glucuronic acid and N-acetylglucosamine. It differs from other glycosaminoglycans in that it is unsulfated, and it does not bind covalently with proteins to form proteoglycan monomers, serving instead as the backbone of proteoglycan aggregates.

Hyaluronan is naturally found in the synovial fluid, cartilage matrix, vitreous humor of the eye, and umbilical cord. In joints, where it serves as a lubricant and shock absorber, it is produced by chondrocytes and synovial cells.

Hyaluronan is not well absorbed orally and for this reason has been chiefly used intra-articularly. An intra-articular preparation was approved by the US Food and Drug Administration (FDA) in 1997 for use in osteoarthritis of the knee. It is included in the guidelines for treatment of osteoarthritis of the American College of Rheumatology and the American Academy of Orthopaedic Surgeons.

Four preparations

Currently, four FDA-approved hyaluronan preparations, extracted from rooster combs, are available in the United States (TABLE 2)⁴³:

- Sodium hyaluronate (Hyalgan)
- Sodium hyaluronate (Supartz)
- HyLAN G-F 20 (Synvisc)
- High-molecular-weight hyaluronan (Orthovisc).

Hyaluronan is naturally found in the synovial fluid, cartilage matrix of the eye, and umbilical cord



All are highly purified natural preparations except for hylan G-F 20, which is chemically cross-linked with added formaldehyde and vinylsulfone to increase its concentration and retention in the joint cavity. Nevertheless, studies have not shown any of the four products to have a longer duration of action or to be more effective than any of the others.^{43,44}

In addition, non-animal-derived hyaluronan preparations, produced by a bacterial fermentation process, are available in Europe. One of these products, Euflexxa, has recently been approved in the United States.⁴⁵ This highly purified hyaluronan has a high molecular weight (2.4–3.6 million daltons). A treatment cycle with Euflexxa is three injections; the effectiveness of repeated treatment cycles has not been established. Euflexxa could be especially useful in the rare patient who is allergic to avian products.

How hyaluronans work

The mechanism of action of hyaluronan was initially termed *viscosupplementation* to indicate restoration of normal viscoelastic properties of the pathologically altered synovial fluid. The purpose of viscosupplementation is to restore rheologic and metabolic homeostasis to the joint.^{46,47} It is thought that this temporary restoration and normalization produced by hyaluronan improves the protective, lubricating, and shock-absorbing effects of synovial fluid.

Other possible mechanisms of action include control of synovial permeability, blockade of inflammation by scavenging oxygen free radicals, and inhibition of matrix metalloproteinases.⁴⁸ Hyaluronan may also protect chondrocytes and promote cartilage matrix synthesis. Whether hyaluronan ameliorates or modifies disease progression has not been determined and remains the subject of much speculation.⁴⁹

The duration of clinical benefit associated with the use of these agents far exceeds their synovial half-life of 2 to 8 days; accordingly, other mechanisms of action of equal or greater importance have been proposed on the basis of investigational studies. These mechanisms include inhibition of inflammatory mediators such as cytokines and prostaglandins, stimulation of cartilage matrix synthesis, inhibition of

cartilage degradation, protection against cellular damage by reactive oxygen species, and a direct effect on nociceptive nerve endings.

Further, in vitro studies of human synovocytes from osteoarthritic joints reveal that exogenous hyaluronan stimulates de novo synthesis of hyaluronan, supporting a further possible benefit from repeat treatment with the compound. Although only limited information is available, an analysis of 255 patients with knee osteoarthritis suggests that these agents are effective and safe when given repeatedly.⁵⁰

Complications of hyaluronan therapy

Significant adverse effects are limited to an acute local reaction, termed the *severe acute inflammatory reaction* (SAIR) or *pseudoseptic reaction*, which has been reported in approximately 2% to 8% of patients who received the cross-linked hylan G-F 20 preparation.⁵¹ SAIRs have not been reported after injection of any of the natural hyaluronans.⁵⁰

Clinical trials of hyaluronans

Intra-articular hyaluronan injection is effective and safe when properly administered. The major factors that influence the therapeutic response are the severity of the disease and the extent of cartilage loss. Additional factors are underlying malalignment of the knee (varus and valgus deformities), muscle weakness, and overloading of the knee joint due to obesity.

In the United States, a large randomized multicenter placebo-controlled trial with sodium hyaluronate (Hyalgan) was carried out in 495 patients with idiopathic osteoarthritis of the knee.⁵² A series of five weekly intra-articular injections of hyaluronate 20 mg was compared with placebo or oral naproxen 500 mg twice daily in a double-blind fashion. Hyaluronate was beneficial in 80% of patients for 26 weeks. Adverse effects were minor and chiefly limited to injection site pain or bruising (23%). Pain relief with hyaluronate was comparable to that with naproxen.

Similar responses were seen in other studies.^{44,53} Analysis by intent to treat and by treatment received both showed a significant benefit from hyaluronan in primary efficacy criteria including pain on walking and the Lequesne algofunctional index. Symptomatic

Severe acute inflammatory reactions have not been reported after injection of any of the natural hyaluronans

benefit persisted for up to 6 months. Preliminary studies showed that the rate of osteoarthritis progression decreased after a series of three hyaluronan injections 4 months apart, suggesting a possible modifying effect on the underlying disease process.

A clinical study of hylan G-F 20 found that 73% of patients had sufficient pain relief to delay or avoid total knee replacement surgery (data on file at Biomatrix Co.; presented at American Academy of Orthopaedic Surgeons meeting, December 3, 1998, Anaheim, CA). Patients were given a course of three hyaluronan injections at 1-week intervals with an 18-month follow-up.

A recently published randomized controlled comparison of high-molecular-weight hyaluronan reported that a regimen of three or four injections was effective and safe, with a low rate of injection site reactions and no serious adverse events.⁴³

The effectiveness of these products has been questioned because a meta-analysis of studies comparing intra-articular hyaluronan with placebo (saline) found the evidence inconclusive.⁵⁴ However, a more recent meta-analysis found that this treatment is effective.⁵⁵ More randomized controlled studies would help to resolve the uncertainty. We should keep in mind that patients with advanced osteoarthritis of the knee with severe or complete loss of joint space ("bone on bone") are unlikely to show significant benefit.

High-molecular-weight hyaluronan may have a greater effect than products with lower

molecular weight, but study heterogeneity limits the reliability of this conclusion. Hamburger et al⁵⁶ reviewed the safety profiles of intra-articular hyaluronans and concluded that, overall, hyaluronan therapy is safe, but the disproportionately high frequency of SAIRs with hylan G-F 20 indicated that differences exist among the available products.

■ FEWER DATA ON OTHER JOINTS

The joints other than the knee most frequently considered for hyaluronan injection in osteoarthritis include the distal and proximal interphalangeal joints, the first carpometacarpal joints, and the first metatarsophalangeal joints. Data on the effectiveness of injecting these joints are limited, and no controlled trials have been performed. The hip is less commonly treated and, for successful needle placement, usually requires guidance with ultrasonography, computed tomography, or magnetic resonance imaging.⁵⁷ At present, FDA approval of hyaluronans is limited to injection of the knee.

Shoulder pain may be due to osteoarthritis. In a recently completed randomized controlled trial, a series of five weekly hyaluronan injections was effective and well tolerated in a significant percentage of the osteoarthritis subgroup with refractory shoulder pain.⁵⁸ Although hyaluronan is approved for the knee only, these preliminary results of glenohumeral joint injection appear promising.

**Hyaluronans
may inhibit
inflammation
as well as
lubricate the
joint**

■ REFERENCES

- Schumacher HR, Chen LX. Injectable corticosteroids in treatment of arthritis of the knee. *Am J Med* 2005; 118:1208–1214.
- Neustadt DH. Osteoarthritis. In: Raket RE, editor. *Conn's Current Therapy*. Philadelphia, W.B. Saunders, 2003:1075–1079.
- Neustadt DH. Current approach to therapy for osteoarthritis of the knee. *Louisville Med* 2004; 51:341–343.
- Felson DT, Naimark A, Anderson J, Kazis L, Castelli W, Meenan RF. The prevalence of knee osteoarthritis in the elderly. The Framingham Osteoarthritis Study. *Arthritis Rheum* 1987; 30:914–918.
- Mandell BF, Lipani J. Refractory osteoarthritis. Differential diagnosis and therapy. *Rheum Dis Clin North Am* 1995; 21:163–178.
- Keating EM, Faris PM, Ritter MA, Kane J. Use of lateral heel and sole wedges in the treatment of medial osteoarthritis of the knee. *Orthop Rev* 1993; 22:921–924.
- Bradley JD, Heilman DK, Katz BP, Gsell P, Wallick JE, Brandt KD. Tidal irrigation as treatment for knee osteoarthritis: a sham-controlled, randomized, double-blinded evaluation. *Arthritis Rheum* 2002; 46:100–108.
- Moseley JB, O'Malley K, Peterson NJ, et al. A controlled trial of arthroscopic surgery for osteoarthritis of the knee. *N Engl J Med* 2002; 347:81–88.
- Neustadt DH. Intra-articular therapy. In: Moskowitz RW, Howell DS, Altman RD, Budwalter JA, Goldberg VM, editors. *Osteoarthritis: Diagnosis and Medical/Surgical Management*, 3rd ed. Philadelphia, W.B. Saunders, 2001:393–411.
- Steinbrocker O, Neustadt DH. Aspiration and injection therapy in arthritis and musculoskeletal disorders; a handbook on technique and management. Hagerstown, MD: Harper & Row, 1972.
- Chandler GN, Wright V. Deleterious effect of intra-articular hydrocortisone. *Lancet* 1958; 2:661–663.
- Silberberg M, Silberberg R, Hasler M. Fine structure of articular cartilage in mice receiving cortisone acetate. *Arch Pathol* 1966; 82:569–582.
- Meyer WL, Kunin AS. Decreased glycolytic enzyme activity in epiphyseal cartilage of cortisone-treated rats. *Arch Biochem Biophys* 1969; 129:431–437.



14. **Mankin HJ, Conger KA.** The acute effects of intra-articular hydrocortisone on articular cartilage in rabbits. *J Bone Joint Surg Am* 1966; 48:1383–1388.
15. **Balch HW, Gibson JM, El-Ghobarey AF, Bain LS, Lynch MP.** Repeated corticosteroid injections into knee joints. *Rheumatol Rehabil* 1977; 16:137–140.
16. **Keagy RD, Keim HA.** Intra-articular steroid therapy: repeated use in patients with chronic arthritis. *Am J Med Sci* 1967; 253:45–51.
17. **Gibson T, Burry HC, Poswillo D, Glass J.** Effect of intra-articular corticosteroid injections on primate cartilage. *Ann Rheum Dis* 1977; 36:74–79.
18. **Raynauld JP, Buckland-Wright C, Ward R, et al.** Safety and efficacy of long-term intraarticular steroid injections in osteoarthritis of the knee: a randomized, double-blind, placebo-controlled trial. *Arthritis Rheum* 2003; 48:370–377.
19. **Armstrong RD, English J, Gibson T, Chakraborty J, Marks V.** Serum methylprednisolone levels following intra-articular injections of methylprednisolone acetate. *Ann Rheum Dis* 1981; 40:571–574.
20. **Hollander JL.** Intrasyndovial corticosteroid therapy in arthritis. *Md State Med J* 1970; 19:62–66.
21. **Saxne T, Heinegard D, Wollheim FA.** Therapeutic effects on cartilage metabolism in arthritis as measured by release of proteoglycan structures into the synovial fluid. *Ann Rheum Dis* 1986; 45:491–497.
22. **Bornstein J, Silver M, Neustadt DH, Berkowitz S, Steinbrocker O.** Intraarticular hydrocortisone acetate in rheumatic disorders. *Geriatrics* 1954; 9:205–210.
23. **Zuckner J, Machek O, Caciolo C, Ahern AM, Ramsey R.** Intra-articular injections of hydrocortisone prednisolone, and their tertiary-butylacetate derivatives in patients with rheumatoid arthritis and osteoarthritis. *J Chronic Dis* 1958; 8:637–644.
24. **Hydrocortisone and osteoarthritis.** *JAMA* 1959; 170:1451 (foreign letters).
25. **Kehr MJ.** Comparison of intra-articular cortisone analogues in osteoarthritis of the knee. *Ann Rheum Dis* 1959; 18:325–328.
26. **Hollander JL.** Osteoarthritis: perspectives on treatment. *Postgrad Med* 1980; 68:161–164, 167–168.
27. **Miller JH, White J, Norton TH.** The value of intra-articular injections in osteoarthritis of the knee. *J Bone Joint Surg Br* 1958; 40-B:636–643.
28. **Friedman DM, Moore ME.** The efficacy of intraarticular steroids in osteoarthritis: a double-blind study. *J Rheumatol* 1980; 7:850–856.
29. **Dieppe PA, Sathapatayavongs B, Jones HE, Bacon PA, Ring EF.** Intra-articular steroids in osteoarthritis. *Rheumatol Rehabil* 1980; 19:212–217.
30. **Valtonen EJ.** Clinical comparison of triamcinolonehexacetonide and betamethasone in the treatment of osteoarthrosis of the knee-joint. *Scand J Rheumatol Suppl* 1981; 41:1–7.
31. **Clemmesen S.** Triamcinolone hexacetonide in intraarticular and intramuscular therapy. *Acta Rheumatol Scand* 1971; 17:273–278.
32. **Thumboo J, O'Duffy JD.** A prospective study of the safety of joint and soft tissue aspirations and injections in patients taking warfarin sodium. *Arthritis Rheum* 1998; 41:736–739.
33. **Neustadt DH.** Complications of local corticosteroid injections [letter]. *JAMA* 1981; 246:835–836.
34. **Fitzgerald RH Jr.** Intrasyndovial injection of steroids: uses and abuses. *Mayo Clin Proc* 1976; 51:655–659.
35. **Gordon GV, Schumacher HR.** Electron microscopic study of depot corticosteroid crystals with clinical studies after intra-articular injection. *J Rheumatol* 1979; 6:7–14.
36. **McCarty DJ.** Treatment of rheumatoid joint inflammation with triamcinolone hexacetonide. *Arthritis Rheum* 1972; 15:157–173.
37. **Sweetnam R.** Corticosteroid arthropathy and tendon rupture. *J Bone Joint Surg Br* 1969; 51:397–398.
38. **Williams JM, Brandt KD.** Triamcinolone hexacetonide protects against fibrillation and osteophyte formation following chemically induced articular cartilage damage. *Arthritis Rheum* 1985; 28:1267–1274.
39. **Bain LS, Balch HW, Wetherly JM, Yeadon A.** Intraarticular triamcinolone hexacetonide: double-blind comparison with methylprednisolone. *Br J Clin Pract* 1972; 26:559–561.
40. **Blake DR, Merry P, Unsworth J, et al.** Hypoxic reperfusion injury in the inflamed human joint. *Lancet* 1989; 1:289–293.
41. **McCarty DJ.** Calcium pyrophosphate dehydrate crystal deposition disease: a current appraisal of the problem. In: Holt PJL, editor. *Current Topics in Connective Tissue Disease*. New York: Longman, 1975:184.
42. **Dieppe PA, Crocker P, Huskisson EC, Willoughby DA.** Apatite deposition disease. A new arthropathy. *Lancet* 1976; 1:266–269.
43. **Neustadt D, Caldwell J, Bell M, Wade J, Gimbel J.** Clinical effects of intraarticular injection of high molecular weight hyaluronan (Orthovisc) in osteoarthritis of the knee: a randomized, controlled, multicenter trial. *J Rheumatol* 2005; 32:1928–1936.
44. **Neustadt DH.** Long-term efficacy and safety of intra-articular sodium hyaluronate (Hyalgan) in patients with osteoarthritis of the knee. *Clin Exp Rheumatol* 2003; 21:307–311.
45. **Kirchner M, Marshall D.** A double-blind randomized controlled trial comparing alternate forms of high molecular weight hyaluronan for the treatment of osteoarthritis of the knee. *Osteoarthritis Cartilage* 2006; 14:154–162.
46. **Balazs EA, Denlinger JL.** Viscosupplementation: a new concept in the treatment of osteoarthritis. *J Rheumatol Suppl* 1993; 39:3–9.
47. **Scale D, Wobig M, Wolpert W.** Viscosupplementation of osteoarthritic knees with Hylan: a treatment schedule study. *Curr Ther Res* 1994; 55:220–232.
48. **Goldberg VM, Buckwalter JA.** Hyaluronans in the treatment of osteoarthritis of the knee: evidence for disease-modifying activity. *Osteoarthritis Cartilage* 2005; 13:216–224.
49. **Kelly MA, Moskowitz RW, Lieberman JR.** Hyaluronan therapy: looking toward the future. *Am J Orthop* 2004; 33(suppl):23–28.
50. **Pagnano M, Westrich G.** Successful nonoperative management of chronic osteoarthritis pain of the knee: safety and efficacy of retreatment with intra-articular hyaluronans. *Osteoarthritis Cartilage* 2005; 13:751–761.
51. **Lussier A, Cividino AA, McFarlane CA, Olszynski WP, Potashner WJ, De Medecis R.** Viscosupplementation with Hylan for the treatment of osteoarthritis: findings from clinical practice in Canada. *J Rheumatol* 1996; 23:1579–1585.
52. **Altman RD, Moskowitz R.** Intraarticular sodium hyaluronate (Hyalgan) in the treatment of patients with osteoarthritis of the knee: a randomized clinical trial. *Hyalgan Study Group. J Rheumatol* 1998; 25:2203–2212.
53. **Huskisson EC, Donnelly S.** Hyaluronic acid in the treatment of osteoarthritis of the knee. *Rheumatology (Oxford)* 1999; 38:602–607.
54. **Lo GH, LaValley M, McAlindon T, Felson DT.** Intra-articular hyaluronic acid in treatment of knee osteoarthritis: a meta-analysis. *JAMA* 2003; 290:3115–3121.
55. **Wang C, Lin J, Chang CJ, Lin YT, Hou SM.** Therapeutic effects of hyaluronic acid on osteoarthritis of the knee. A meta-analysis of randomized controlled trials. *J Bone Joint Surg Am* 2004; 86-A:538–545.
56. **Hamburger MI, Laxhanpal S, Moobar PA, Oster D.** Intra-articular hyaluronans: a review of product-specific safety profiles. *Semin Arthritis Rheum* 2003; 32:296–309.
57. **Wakefield RJ, Gibbon WW, Emery P.** The current status of ultrasonography in rheumatology. *Rheumatology (Oxford)* 1999; 38:195–198.
58. **Altman R, Moskowitz R, Jacobs S, et al.** A double-blind, randomized trial of intra-articular injection of sodium hyaluronate (Hyalgan) for the treatment of chronic shoulder pain [abstract]. *Arthritis Rheum* 2005; 52(suppl):S461.

ADDRESS: David H. Neustadt, MD, Medical Towers South, 234 East Gray Street, Suite 328, Louisville, KY 40202.